

Case Report

Symptomatic Cholelithiasis in a Male Infant: Two-Year Follow-Up and Surgical Management – A Case Report

Manuel Gonzalez-Plascencia¹, Antonio Ignacio del Rio-Robles¹¹Department of Pediatric Surgery, General Hospital of Zacatecas “Luz González Cosío”, Zacatecas, Mexico

This work is licensed under **Creative Commons Attribution - Non Commercial 4.0 International License**.

e-ISSN: 2830-5442

Corresponding author:

Manuel Gonzalez-Plascencia
manuelgonzalezcharro@gmail.com

Published:28th February 2026**DOI:**

<https://doi.org/10.58427/apghn.5.1.2026.37-44>

Citation:

Gonzalez-Plascencia M, del Rio-Robles AI. Symptomatic cholelithiasis in a male infant: two-year follow-up and surgical management: a case report *Arch Pediatr Gastr Hepatol Nutr.* 2026;5(1):37-44

Abstract:

Background: Infant cholelithiasis is an uncommon and often idiopathic condition, frequently detected incidentally due to nonspecific symptoms. Although spontaneous resolution is common during infancy, the lack of standardized management guidelines complicates decision-making, particularly in symptomatic patients. Long-term data describing the natural history and indications for surgical intervention remain limited.

Case: We describe a male infant diagnosed with gallstones at four months of age following recurrent episodes of colicky abdominal pain. Extensive laboratory evaluation excluded hemolytic, metabolic, infectious, and anatomical causes. Serial ultrasonography confirmed persistent gallstones without inflammatory changes. Given the patient's clinical stability, expectant management with close follow-up was initially chosen, including periodic clinical assessments, annual ultrasound examinations, and biochemical testing. Despite normal growth and normal biochemical results, the patient experienced intermittent recurrent localized abdominal pain over a two-year period. Because of persistent symptoms, definitive surgical management was indicated, and an open cholecystectomy was performed at two years of age. Intraoperative findings revealed two black pigment stones consisting of calcium bilirubinate, without anatomical abnormalities. Postoperative recovery was uneventful, and the patient remained asymptomatic during follow-up.

Discussion: This case illustrates the challenges of managing idiopathic infant cholelithiasis, particularly regarding the timing of surgery. While conservative management is appropriate for asymptomatic patients, persistent or recurrent symptoms justify surgical intervention. This extended follow-up provides insight into the persistence of the disease beyond infancy.

Conclusion: Individualized management is essential in infant cholelithiasis. This case supports surgical treatment in symptomatic patients with persistent gallstones, even in the absence of identifiable risk factors.

Keywords: cholecystectomy, cholelithiasis, gallstones, infant, pediatric cholelithiasis

Introduction

Gallstones are defined as solid deposits, including stones or biliary sludge, within the gallbladder (cholelithiasis) or biliary tract, arising from altered bile composition, gallbladder motility, and genetic or metabolic factors.^{1,2} In adults, prevalence is up to 16%, especially in older adults.³ The widespread use of ultrasonography has enabled earlier and more accurate diagnosis, often detected incidentally.⁴ In pediatric populations, prevalence is less than or equal to 2%, with 33–40% of cases being asymptomatic.^{2,5} Distribution varies by age and sex; more frequent in girls older than 10 years and in boys younger than 2 years. In infants, cholelithiasis is rare and often idiopathic, though it may be linked to hereditary, metabolic, or infectious factors, prolonged parenteral nutrition, or medication use.² Diagnosis is challenging, since symptoms are nonspecific and may overlap with other abdominal disorders.⁶ We report a case of idiopathic cholelithiasis diagnosed at 4 months of age, initially managed expectantly. The patient ultimately required cholecystectomy at 2 years, underscoring its low incidence, diagnostic challenges, and the need for standardized management protocols.

Case

A two-year-old boy, delivered at term following a fifth uneventful pregnancy with appropriate prenatal care, did not require resuscitation and was discharged without perinatal complications. He was exclusively breastfed, received all recommended vaccinations, and had a normal newborn screening test. The child lives in adequate sanitary conditions, and his parents were healthy, with no relevant family history of hemolytic, metabolic, or hepatobiliary disease. Subsequent follow-up confirmed normal growth and neurological development.

At four months of age, the patient presented with recurrent episodes of paroxysmal abdominal pain, characterized by sudden-onset, high-pitched, inconsolable crying associated with irritability, body flexion, and crying triggered predominantly after feeding, partially relieved by spontaneous calming, and clearly distinct from typical infantile colic. There were no associated symptoms such as fever, vomiting, diarrhea, jaundice, acholic stools, or failure to thrive.

Due to recurrent abdominal pain, the patient was taken by his parents to a private clinic, where an ultrasound revealed gallstones. However, no written report was provided at that time, and the patient was subsequently referred for pediatric surgical evaluation without documentation. On examination, the child was afebrile and hemodynamically stable, with intermittent irritability and suspected right upper quadrant discomfort, without abdominal distension or palpable masses.

Initial laboratory evaluation included complete blood count, serum biochemistry, electrolytes, lipid profile, coagulation test, pancreatic enzymes, hemolysis panel (reticulocyte count, lactate dehydrogenase, haptoglobin, and peripheral smear), inflammatory markers, and urinalysis, all which were within normal limits. As shown in **Table 1**, liver function tests demonstrated a transient cholestatic pattern, with elevated alkaline phosphatase and gamma-glutamyl transferase and mild transaminase elevation, without progressive hyperbilirubinemia. These findings effectively ruled out hemolytic, infectious, and metabolic causes of cholelithiasis.

Table 1. Initial liver function tests with appropriate values for a 4-month-old infant

Biochemical variable	Normal for age	Result
Total bilirubin (mg/dl)	0.05-0.68	0.78*
Indirect bilirubin (mg/dl)	0-1	0.32
Direct bilirubin (mg/dl)	0.05-0.30	0.46*
Alkaline phosphatase (U/L)	134-518	655*
Albumin (g/dl)	2.8-4.7	4.09
Total protein (g/dl)	4.2-7.4	6.2
Alanine transaminase (ALT) (U/L)	5-33	49*
Aspartate transaminase (AST) (U/L)	20-67	74*
Gamma-glutamyl transpeptidase (GGT) (U/L)	5-65	82*

* = Outside the reference range

Other frequent causes of abdominal pain in infancy, including cow's milk protein allergy and functional gastrointestinal disorders, were excluded based on exclusive breastfeeding, absence of alarm signs (poor weight gain, persistent vomiting, gastrointestinal bleeding), normal physical examination, and appropriate developmental progression. Institutional ultrasound (**Figure 1A and 1B**) demonstrated a heterogeneous gallbladder with a 1.3 mm wall and two hyperechoic oval images located in the gallbladder neck, measuring 13 and 7 mm, respectively, with posterior acoustic shadowing. No biliary duct dilatation, choledochal cyst, or structural abnormalities were identified, and there were no sonographic signs of cholecystitis.

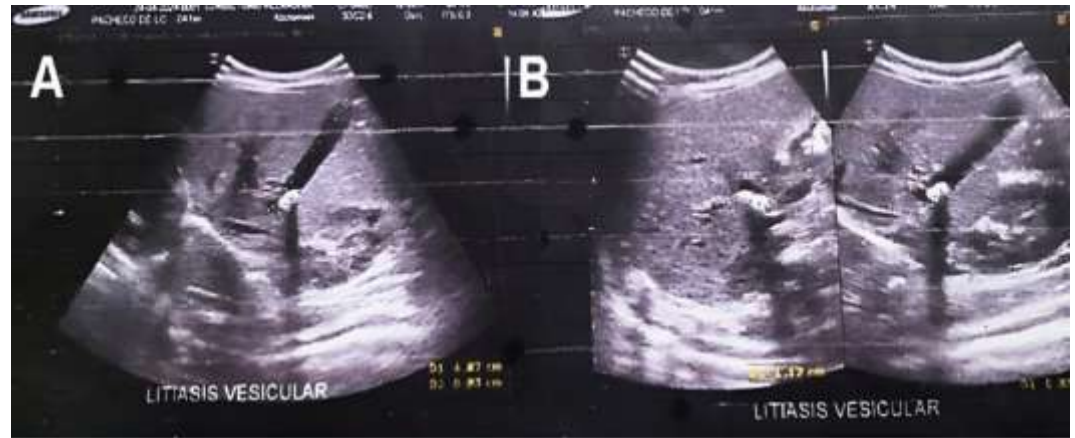

Figure 1. Ultrasonographic findings of the gallbladder.

- a) Longitudinal ultrasound view demonstrating a distended gallbladder with a thin, regular wall and preserved mural stratification. Within the gallbladder neck, a well-defined echogenic focus with strong posterior acoustic shadowing is identified, consistent with a solid gallstone. No pericholecystic fluid or gallbladder wall thickening is observed, findings that argue against acute cholecystitis.
- b) Additional views in longitudinal and oblique orientations reveal two discrete echogenic foci, both casting clean, sharp acoustic shadows, located within the gallbladder lumen. Their non-mobile appearance (given the similar position across sequential frames) suggests they are impacted or partially impacted pigment stones. The surrounding biliary tree shows no evidence of ductal dilatation.

Given the patient's clinical stability, young age, absence of complications, and socioeconomic limitations affecting access to specialized care, expectant management was initially selected. This approach was based on pediatric guidelines supporting conservative management in asymptomatic or mildly symptomatic infants. Follow-up consisted of scheduled clinical evaluations every 6 months, parental symptom diaries, growth and nutritional monitoring, serial abdominal ultrasonography annually, and biochemical testing including liver function tests, bilirubin levels and complete blood count. Laboratory parameters were consistently normal during follow-up, supporting an idiopathic etiology, while serial ultrasounds demonstrated persistent gallstones without change in size or number. Also, the patient remained clinically asymptomatic throughout the first year, with no recurrence of abdominal pain and normal growth. During the second year of follow-up, however, he developed two consecutive episodes of localized colicky abdominal pain within a one-week period, which prompted medical consultations. These episodes were managed conservatively with intermittent oral analgesics (acetaminophen), with adequate symptomatic relief. Due to persistent, recurrent colicky pain over a two-year period, definitive surgical management was indicated in accordance with pediatric surgical recommendations, and an open cholecystectomy was performed at two years of age after completion of the preoperative evaluation.

On admission, the patient was asymptomatic, afebrile, and hemodynamically stable, weighing 12.2 kg and measuring 85 cm. Physical examination revealed intact neurological status, appropriate social interaction, clear lung fields, a regular heart rhythm without murmurs, and a soft, non-tender abdomen with normal bowel sounds and no organomegaly. The patient underwent open cholecystectomy via a right subcostal Kocher incision. Intraoperative findings included a gallbladder measuring approximately 5 × 2 cm with minor adhesions at the neck (Parkland grade II). Two gallstones were identified: one in the gallbladder body and another in Hartmann's pouch. Both were hard, irregular, and black, consistent with pigment stones, the most common type in pediatric patients, associated with calcium bilirubinate precipitation. These findings are shown in **Figure 2A and 2B** depicting the gallbladder and extracted stones. No acute inflammation or anatomical anomalies were observed.

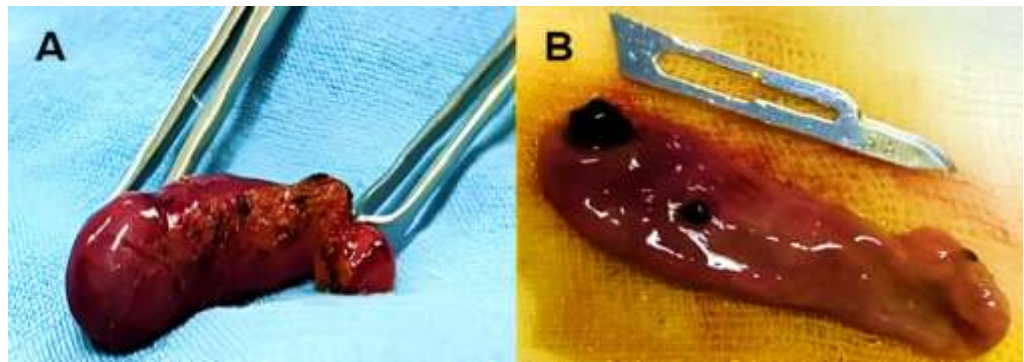


Figure 2. Macroscopic appearance of the gallbladder and pigment stones.

- a) Intact gallbladder with thin walls and a smooth, glistening serosal surface, without features of acute inflammation. Mild focal congestion is noted near the neck, correlating with the minor adhesions described intraoperatively. No mural thickening, perforation, or anatomical anomalies are observed.
- b) Gallbladder opened longitudinally, revealing a preserved and uniformly smooth mucosal surface without ulceration or erosions. Two black pigment stones with irregular contours and firm consistency are identified within the lumen, located in the body and infundibulum. Their dark coloration and density are consistent with calcium bilirubinate pigment stones, the most common type in pediatric patients.

Histopathological examination revealed a gallbladder with congested mucosa and nonspecific chronic changes, without dysplasia or malignancy. Two black pigment stones composed predominantly of calcium bilirubinate, with no significant cholesterol component, were confirmed. The postoperative course was uneventful. The patient was discharged 36 hours later in good condition. Outpatient follow-up demonstrated favorable clinical progress, appropriate weight gain, and no recurrence of abdominal symptoms. Parents were advised to attend scheduled pediatric follow-

up visits and seek emergency care if alarming signs developed. Written informed consent was obtained from one of the parents for the publication of this case report.

Discussion

Cholelithiasis in childhood, particularly in infants under one year of age, is a rare but increasingly recognized clinical phenomenon due to the widespread use of abdominal ultrasonography.⁴ Its etiology differs markedly from that observed in adults, with a predominance of secondary causes and a smaller, though still significant, proportion of idiopathic cases. The literature indicates that between 30% and 50% of gallstones diagnosed in the first months of life lack an identifiable causal factor, which underscores the need for rigorous diagnostic evaluation to classify a case as idiopathic.¹

The etiological analysis is based on ruling out chronic hemolysis, liver disease, anatomical abnormalities, systemic infections, parenteral nutrition, and exposure to lithogenic drugs such as ceftriaxone, furosemide, or somatostatin analogs.² Although black pigment gallstones are classically associated with hemolytic diseases or conditions that cause hyperbilirubinemia, several pediatric series report that a significant proportion of infants and children with pigment stones lack identifiable risk factors, suggesting an idiopathic form. These stones remain predominantly pigment (calcium bilirubinate) and could form through biliary supersaturation with unconjugated bilirubin and precipitation of calcium salts.⁷

Ultrasound evidence plays a central role in the identification of cholelithiasis and its complications. Ultrasound has high sensitivity and specificity for detecting stones in childhood, making it the technique of choice due to its availability and safety.⁴ In infants, its differential diagnostic value is especially relevant because the symptoms are often nonspecific and difficult to interpret.¹ Ultrasound confirmation by demonstrating mobile hyperechoic foci with posterior acoustic shadowing and excluding significant wall thickening, pericholecystic fluid, or dilation of the common bile duct allows differentiation between uncomplicated stones and inflammatory processes such as acute cholecystitis or choledocholithiasis.⁸

The literature agrees that most infants diagnosed with gallstones experience spontaneous resolution, especially when the stones are small or constitute biliary sludge.⁵ It has been documented that between one-third and one-half of patients under 12 months of age experience complete resolution within an average of nine months, associated with physiological liver maturation. This trend supports the recommendation of expectant management in asymptomatic cases, along with serial ultrasounds every 3 to 6 months.⁹ Furthermore, the use of ursodeoxycholic acid remains controversial: the most recent studies show higher resolution rates in untreated patients, suggesting that the improvement reflects the natural history rather

than a true pharmacological effect. Moreover, its efficacy is limited in pigment stones, which are predominant in the pediatric population.¹⁰

However, guidelines agree that the presence of persistent symptoms, especially recurrent colicky pain, is a formal indication for cholecystectomy, regardless of age.^{1,4} Evidence indicates that symptomatic infants have a higher risk of complications such as cholecystitis, pancreatitis, or stone migration, even without initial signs of inflammation.⁸ Regarding the surgical approach, laparoscopic cholecystectomy is the standard in most centers due to its postoperative advantages.^{1,9} Nevertheless, in young infants, open surgery remains a completely valid and safe alternative.¹ Several pediatric reports show that there are no significant differences in complications between the two methods in children under one year of age, provided the technique is adapted to the anatomical context and the surgeon's experience.^{1,9}

This case adds value to the literature by exemplifying an idiopathic presentation of pigment stones in an infant without predisposing factors, whose persistent symptoms warranted intervention. It also underscores the importance of strictly applying diagnostic exclusion criteria, appropriately using ultrasonography as the primary diagnostic tool, and recognizing that, although spontaneous resolution is common, persistent symptoms necessitate definitive management.^{1, 4, 5} The experience accumulated in these cases contributes to the understanding of the pathophysiology of lithiasis in infants and strengthens the evidence supporting surgical indications at an early age.

Conclusion

Cholelithiasis in infants is rare and often resolves spontaneously, but some cases persist and require intervention. This report highlights idiopathic pigment stones occurring without hemolysis or identifiable risk factors, supporting their recognition as a distinct entity. Persistent symptoms and stable or enlarging stones on serial ultrasounds justify definitive surgical management, regardless of age. Limited access to specialized care can prolong symptom burden, underscoring the need for tailored follow-up protocols in resource-constrained settings. Further research is necessary to elucidate the mechanisms of idiopathic pigment stones in early life and to establish standardized criteria for follow-up and surgical indication.

Acknowledgement

Informed written consent was obtained from one of the parents.

Conflict of Interest

The authors are not members of an advisory board of a pharmaceutical company, nor have they received any financial support from a commercial source for this article. The findings, opinions, or viewpoints contained in this article are those of the authors and do not represent an official position of the institution where they work.

Funding Statement

No grants, equipment, medications, or other support were received for the work described in this article or for its writing.

References

1. Espinosa-Saavedra D, Flores-Calderón J, González-Ortiz B, Rodríguez-González P. [characteristics of pediatric patients with biliary lithiasis. Immediate post-operative evolution]. *Rev Med Inst Mex Seguro Soc.* 2014;52 Suppl 2:S74-7.
2. Zdanowicz K, Daniluk J, Lebensztejn DM, Daniluk U. The etiology of cholelithiasis in children and adolescents-a literature review. *Int J Mol Sci.* 2022;23(21). <https://doi.org/10.3390/ijms232113376>
3. Agawu A, Kanagawa C, Wong J, Shults J, Feudtner C, Bewtra M. Pediatric cholelithiasis in the united states: National hospitalization trends, 2006 to 2019. *J Pediatr Gastroenterol Nutr.* 2023;77(6):741-7. <https://doi.org/10.1097/mpg.0000000000003959>
4. Ünlüsoy Aksu A, Genel N, Şahin G, Özbay Hoşnut F, Tok A, Karaman A. Cholecystectomy in children: Indications, clinical, laboratory and histopathological findings and cost analysis. *Turk J Pediatr.* 2024;66(4):473-80. <https://doi.org/10.24953/turkjpediatr.2024.4921>
5. Bhaumik K. Asymptomatic cholelithiasis in children: Management dilemma. *J Indian Assoc Pediatr Surg.* 2021;26(4):228-33. https://doi.org/10.4103/jiaps.JIAPS_107_20
6. Lehane A, Alemayehu H. Non-congenital biliary disease in infants. *Semin Pediatr Surg.* 2025;34:151504. <https://doi.org/10.1016/j.sempedsurg.2025.151504>
7. Vitek L, Carey MC. New pathophysiological concepts underlying pathogenesis of pigment gallstones. *Clin Res Hepatol Gastroenterol.* 2012;36(2):122-9. <https://doi.org/10.1016/j.clinre.2011.08.010>
8. Pogorelič Z, Lovrić M, Jukić M, Perko Z. The laparoscopic cholecystectomy and common bile duct exploration: A single-step treatment of pediatric cholelithiasis and choledocholithiasis. *Children (Basel).* 2022;9(10). <https://doi.org/10.3390/children9101583>
9. Quirós Espigares N, Rubio Santiago J, Rodríguez Barrera S, Ortiz Tardío J. Colelitiiasis infantil: Aportación de 51 nuevos casos y revisión bibliográfica. *Acta pediatr esp.* 2014:e194-e201.
10. Çakar S, Eren G, Erdur CB, Önder M, Pelek Ş, Alpdoğan S, et al. Cholelithiasis in infants: Risk factors, management, and the role of ursodeoxycholic acid. *Children (Basel).* 2024;11(12). <https://doi.org/10.3390/children11121553>